

# Anatomical architecture and molecular study of skin immune system: A brief review

Sagar N. Ande<sup>1</sup>, Achal S. Khade<sup>1</sup>, Ravindra L. Bakal<sup>1</sup>, Deepak S. Mohale<sup>2</sup>

<sup>1</sup>Department of Pharmacology and Toxicology, Dr. Rajendra Gode Institute of Pharmacy, Amravati, Maharashtra, India, <sup>2</sup>Department of Pharmacology and Toxicology, P. Wadhvani College of Pharmacy, Yawatmal, Maharashtra, India

**Correspondence:**

Sagar N. Ande, Dr. Rajendra Gode Institute of Pharmacy, University-Mardi Road, Amravati - 444 602, Maharashtra, India. E-mail: sagar986ande@gmail.com

**How to cite this article:**

Ande SN, Khade AS, Bakal RL, Mohale DS. Anatomical architecture and molecular study of skin immune system: A brief review. *Innov Pharm Pharmacother* 2022;10(2):46-51.

**Date of Submission:** 20-05-2022

**Date of Revision:** 10-06-2022

**Date of Acceptance:** 16-06-2022

**Source of Support:** Nil.

**Conflicts of Interest:** None declared.

## ABSTRACT

Our skin is the body's external layer, spanning around 1.8 m<sup>2</sup> and acting as the first link for defense against external illnesses and poisons. In addition to drop loss of water and aiding with body thermoregulation, the skin has an important action in homeostasis. The skin's structure and cellular composition work together to stop infections and cope with physical and chemical stresses from the outside environment. This article discusses the involvement of structural cells in barrier immunity, such as keratinocytes, fibroblasts, and adipocytes. We also debate specialized immune cells found in steady-state skin, such as mononuclear phagocytes like Langerhans cells, dermal macrophages, and dermal dendritic cells, in addition to resident memory T cells. As people age, they are more likely to get cancer and skin diseases. The epidermis and dermis shrink, water loss increases, and collagen and elastin break down as we age. The immunological makeup of the skin has also changed, with fewer Langerhans cells, weaker antigen-specific immunity, and more regulatory populations, such as Foxp<sup>3</sup> + regulatory T cells. The elderly have weaker barrier immunity as a result of these changes, which may explain why they are more susceptible to cancer and infections.

**Keywords:** Dermis, epidermis, immune response, inflammation, skin injury, wound healing

## Introduction

The concept is about organ-specific immunity and how it affects the evolution of diseases, like infectious diseases. Barrier epithelium immune responses, complex organ immune responses, and immunologically favored organ immune responses are the three broad types of tissue immune responses in this context. The skin is an example of an organ that functions as a mechanical and immunological barrier in pathogen defense and bodily homeostasis.<sup>[1]</sup> The first line of defense against pathogenic microbes is tissues that create host–environment interactions, such as mucosal surfaces. The majority of the body's skin is organized similarly, but select areas, such as the foot, scalp, and genitalia, have highly specialized adaptations. The epidermis, dermis, cutaneous appendages, and subcutaneous tissue make up the skin. The anatomy of the skin

and its inherent defensive mechanisms will be discussed in this study, with an emphasis on skin-resident immune cells and their aids to tissue restoration.<sup>[2]</sup> The skin defends the host against invasion using physical barriers, biomolecules, and a complex network of resident immune and non-immune cells and skin structures.<sup>[3]</sup> Furthermore, resident immune cells accelerate epidermal physiological processes in the absence of a trigger. The skin's defense and protection mechanisms are examined, as well as their contributions to tissue homeostasis.

## The Skin's Structure

The epidermis and dermis are the two primary layers of skin. The epidermis is made up of stratified keratinized squamous epithelium and is the most superficial layer.<sup>[1]</sup> The palms of the hands are the thickest, followed by the palms of the feet. The epidermis of the soles of the feet also lacks blood vessels and nerve endings, but it is bathed in intestinal fluid from the dermis, which supplies oxygen and nutrients while draining as lymph. From the lowest germinative layer to the most superficial stratum corneum, the epidermis has many

### Access this article online

Website: [www.innpharmacotherapy.com](http://www.innpharmacotherapy.com)

e-ISSN: 2321-323X

p-ISSN: 2395-0781

This is an open access journal, and articles are distributed under the terms of the Creative Commons Attribution NonCommercial Share Alike 4.0 License, which allows others to remix, tweak, and build upon the work non-commercially, as long as appropriate credit is given and the new creations are licensed under the identical terms.

layers (strata) of cells (a thick horny layer). Epidermal cells begin in the germinative layer and progress to the skin's surface, changing throughout time. On the surface of flat, thin, non-nucleated, and dead cells, the fibrous protein keratin has replaced plasma.<sup>[4]</sup>

Epidermis is composed of following five layers which are<sup>[4-7]</sup> (1) Stratum corneum, (2) Stratum lucidum, (3) Stratum granulosum, (4) Stratum spinosum, and (5) Stratum Basale [Figures 1 and 2].

## Keratinocytes

Keratinocytes in later stages of maturation may be seen in stratum corneum. It helps to preserve hydro electrolytic equilibrium by removing the majority of potentially harmful substances. Melanocytes in the basal layer produce melanin and promote the production of main histocompatibility complex class II (MHC-II) proteins, which help protect DNA from UV radiation.<sup>[1,2]</sup> A layer of undifferentiated cells in continual mitotic activity makes up the stratum basale (or basal stratum). Cells develop from the basal stratum to create the stratum spinosum (or spinous stratum), which generates keratin.<sup>[4,5]</sup> Keratinocytes with blackened granules in their cytoplasm generate keratin-forming proteins as well as lipids, which make up the stratum granulosum.<sup>[5]</sup>

In the stratum basal, stem cells create keratinocytes. Mitosis stops when keratinocytes travel more than three cells away from the dermis. Vesicles secrete lipids, which spread over the cell surface and seal the layer. If the stratum spinosum is damaged, an epidermal water barrier arises to prevent water loss and dehydration. Because they are deprived of nutrients, cells near the surface perish. Wounds to the skin are partially mended by keratinocyte migration to cover the gap formed by the wound. The initial keratinocytes to engage in the healing originate from the hair follicle's bulge area and will only survive for a short time.<sup>[6,7]</sup> Keratinocytes generate defensins and cathelicidins, which are part of a highly conserved eukaryotic cell defense system. Antimicrobial peptides (AMPs) are produced on the damaged epithelium to prevent microorganism invasion by killing pathogens, activating immune cells, and changing the cytokine profile. Keratinocytes generate cytokines such as interleukin-1 (IL-1), IL-6, IL-10, IL-17, IL-18, IL-22, and tumor necrosis factor alpha (TNF-alpha). Heat, ultraviolet light, water loss, pathogenic bacteria, fungus, parasites, and viruses can cause damage to keratinocytes.<sup>[7]</sup>

## Dermis

It may be found under the epidermis. Connective tissue and a matrix containing collagen fibers that interact with elastic fibers make up the dermis. Fibroblasts, macrophages, and mast cells make up the dermis. Elastic fibers are caught when the skin is stretched too far, it gives long-lasting scars of stretching, and this can form due to pregnancy or excess fat deposition in body. Collagen strands connect to water and give elasticity to skin, but as this capacity declines with age, wrinkles occur.<sup>[1-7]</sup> The dermis contains blood and lymph arteries, sensory nerve endings, sweat glands and their ducts, hairs, erector pili muscles, and the sebaceous gland. The dermis is divided into two basic regions: The papillary area and the reticular layer. Above the epidermis is the epidermis, which is the top layer of skin. It is irregular and bears fingerlike projections called dermal

papillae on its superior surface. The deepest area of the body, the reticular papillae, includes blood vessels, sweat and oil glands, as well as deep pressure sensors. It has a mix of collagen fibers that help to strengthen the skin and elastic fibers that help the skin retain its flexibility.<sup>[10]</sup>

Collagen fiber: Collagen is a fibrous, rigid, and insoluble protein that accounts for 1/3 of the protein in the human body. As seen above, the dermis is separated into two layers: Papillary and reticular. The reticular dermis is made up of a thicker layer of dense connective tissue, a layer of blood vessels that are intimately interconnected, and end course bundles of collagen fibers that are organized in a layer parallel to the surface. Collagen promotes wound healing by recruiting new skin cells to the area.<sup>[1-5]</sup> It promotes healing and lays the groundwork for the future tissue growth. The collision of ultraviolet photons in sunlight causes collagen strands to break down more quickly, causing aberrant elastic to grow up. Fat silicone or implants are usually utilized to bridge larger gaps since collagen has the capacity to sense relatively tiny openings.<sup>[8-10]</sup>

## Immune System of Skin

The major function of the skin is to protect body from invasion, physical barriers, biomolecules, and a huge network of resident immune and non-immune cells and skin structures are used to accomplish this. Furthermore, in the absence of a stimulus, resident immune cells increase epidermal physiological processes.<sup>[11,12]</sup> The skin's defense and protection techniques, as well as their contributions to tissue homeostasis, are described below.

## Skin Barriers

To perform protective functions, some barriers (physical, biomolecules, and pH of skin) aid skin in that role. These skin barriers are as below.<sup>[13]</sup>

## Physical Barriers

Corneocytes in the stratum corneum play a significant part in barrier function of epidermis. The stratum corneum is made up of three layers that work as an outside-in barrier to keep foreign chemicals and bacteria out, as well as an inside-out barrier to keep water in. Inflammatory skin disorders may be exacerbated by the breakdown of components of the skin's physical barriers.<sup>[8-12]</sup>

## Biomolecules of the Skin

The primary groups of macromolecules that engage in skin defense by breaking bacterial membranes are AMPs and lipids. The defense in and the cathelicidin AMP families are generated by a number of cells in the skin, including keratinocytes, macrophages, dendritic cells, monocytes, and fibroblasts are some of the cells that make up the human body, as well as sweat and sebaceous glands.<sup>[11-13]</sup>

## AMPs

Innate immunity is aided by antimicrobial peptidase soluble components released into the cutaneous surface" AMPs Beta sheets file

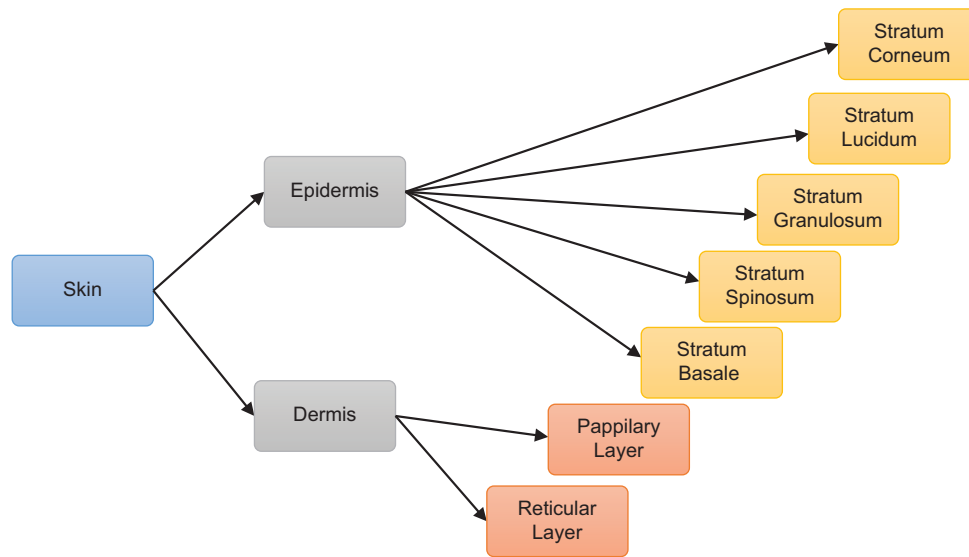


Figure 1: Schematic representation of layers of skin

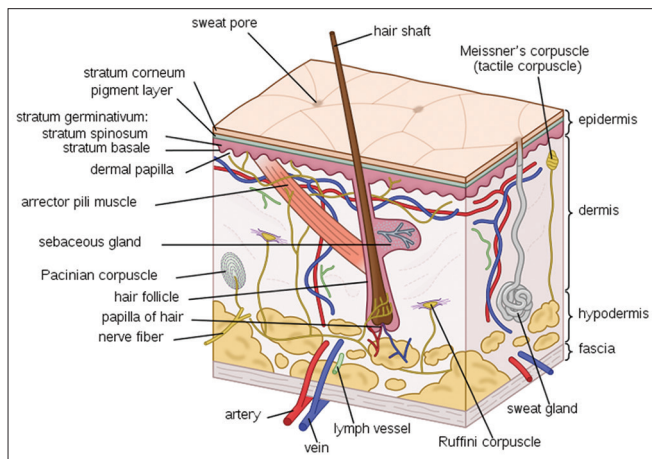


Figure 2: Internal structure of skin

linear peptide is from alpha helix for primarily two distinct secondary structure disulfide rich peptidase.<sup>[11]</sup> AMPs are classified as endogenous antibiotics since they have the ability to destroy a variety of bacteria by disrupting their membranes. They have antibacterial action throughout a wide range and can destroy Gram-positive bacteria, viruses, and fungi. Secret AMPs are produced by keratinocytes and other skin cells which are eccrine gland cells, mast cells, and sebocytes.<sup>[8,9]</sup> The synthesis of AMPs is a crucial part of the dynamic defense system. In this skin, several AMPs are expressed in a constitutive manner. In harmful conditions like as skin damage or infection, the production of others is greatly boosted. The majority of AMPs are produced as pro peptides that are activated following proteolytic cleavage of their precursor components. The defensive and other cathelin peptide families are two major and well-studied AMP families in human skin. Human beta defensin (HBD)2 was the first AMP identified from a kingfish. HBD2 is particularly effective against Gram-negative bacteria, although HBD 3, which belongs to the same AMP family, has a wider antibacterial and infectious range. AMPs expression in the skin is enhanced in response to infection or injury due to increased keratinocyte production and deposition from recruited neutrophil degranulation.<sup>[14]</sup>

## Cathelicidine

It is secreted by epithelial cells. Cathelicidine AMPs are polypeptides that are kept largely in lysosomes, macrophages, and polymorph nuclear leukocytes. Cathelicidine is a substance that plays an important function in mammalian innate immunological protection against bacterial invasion. LL-37, a 37-amino-acid long peptide with wide antibacterial action, was the first active cathelicidin discovered. After fusing with lysosomes in macrophages, cathelicidine quickly destroys the lipoprotein membrane of microorganisms encapsulated in phagosomes. Cathelicidin has been found to provide enhanced protection against microorganisms when present in the skin. Antimicrobial action of mature cathelicidine peptides is fast and broad-spectrum. Cathelidines are highly expressed and have a variety of roles in skin protection. Some cell types in the skin, including mast cells, keratinocytes eccrine ducts, and neutrophils, express the human cathelicidine precursor protein (HCAP18). In neutrophils, cathelidines are converted to active peptides like IL-37, as well as more powerful peptides in perspiration. Importance of the growth factor in human keratinocytes, functions such as insulin-like growth factor-1, and transforming growth factor alpha increases the development of cathelicidine and defenses.<sup>[15]</sup>

## Skin's pH

The skin's pH ranges from 5.4 to 5.9, making it an unsuitable environment for infections. Furthermore, the considerable pH difference among the skin and the blood (PH 7.4) acts as a secondary defense mechanism if micro penetrate the skin tissue and enter the circulation. A low pH is maintained by the skin in a variety of ways. Filaggrin corneocytes generate histidase, which breaks down a filament-related protein that binds keratin fiber into histidine, which is subsequently transformed into the acidic metabolite urocanic acid by histidase. The acidity of the stratum cornea has been connected to this. The acidity of the skin is also influenced by fatty acids generated in the stratum corneum.<sup>[16]</sup>

## The Skin's Immune Cells

Skin-resistant immune cells maintain tissue homeostasis and serve as sentinels, collecting antigen from the surrounding environment. Both myeloid and lymphoid cell subsets are present in the skin in a constant state [7].<sup>[17]</sup> The place of every immune cell type in skin tissue and its function while homeostatic inflammation and wound recovery are mentioned in Table 1 overview of skin's immune system, as well as their function in inflammation and wound healing.<sup>[18]</sup>

### Myeloid Cells

Langerhans cells, dermal dendritic cells, macrophages, mast cells, and eosinophils are all skin-resident myeloid cells. Because neutrophils are rarely seen in healthy skin, they are not called skin-resident cells. Myeloid cells react fast in inflammatory circumstances and release pro-inflammatory mediators, causing local cell activation and peripheral immune cell infiltration of the affected area.<sup>[19]</sup>

### Langerhans Cells

Langerhans cells are the only type of myeloid cell found in epidermis. The epidermis's basal and suprabasal layers contain Langerhans cells. It starts in the bone marrow and migrates into the epithelium to carry out antigen recognition and presentation, with their migratory role increasing during inflammation. Dendritic cell membranes called Langerhans cells can be found in the epidermis' basal and suprabasal layers, as well as the respiratory, digestive, and urogenital tract epithelium. This was part of the cutaneous immune system, and it was responsible for antigen presentation. Antigen is collected from peripheral tissue, transported to a lymph node in the area, delivered to cells, and adaptive immune responses are generated. Despite having

considerable immunogenic properties, Langerhans cells may play a function in tolerance mediation.<sup>[20]</sup>

**Dermal Dendritic Cells:** Dendritic cells (also known as accessory cells) are antigen-presenting cells in the mammalian immune system. A type of immune cell located in a tissue like the skin that boosts immunological responses by displaying antigen on its surface, as well as two other immune system components. Through afferent lymphocytes, DCs capture antigen and move to T-cell rich regions (secondary lymphoid organ). During this time, DCs lose the ability to absorb more antigen.<sup>[20]</sup>

### Macrophages

Macrophages live in the skin's dermal layer and require IL-34 to survive. Production of IL-4 and IL-13 cytokines alternatively activates macrophages and enhances endocytosis. Increased MHC class two expression. Phagocytosis is a process that macrophages employ to kill and remove undesirable particles from the body. The phagocytosis means to consume a sale, the mechanism is as follows as the macrophages engulf the particle, the enzyme is then released into the phagosomes by a lysosome a macrophage organelle. Macrophages remove a wide range of unwelcome foreign bodies from the body. However, because of skin barrier, foreign matter cannot invade the body.<sup>[21]</sup>

### Mast Cells

Mast cells can be seen in skin's dermal layer. Mast cells are formed from bone marrow that penetrates skin and grows locally in response to environmental cells. Mast cells can be seen in all areas of the human skin, but they are more common in the arms and legs. The density

**Table 1: Summary of the skin's immune system summarizes the location of each immune cell type in the skin tissue, as well as their involvement during homeostasis inflammation, and wound healing**

S.No.	Immune cell type	Location	Inflammatory function	Function during wound healing
1	Langerhans cell and DC cell	Langerhans cell: Epidermis Dc cell: Papillary dermis	Induce Tcells responses and Creates pro-inflammatory cytokines peripheral immune cells	Promote angiogenesis, Granulation tissue formation, growth factor synthesis
2	Macrophages/monocytes -derived macrophages	Papillary and reticular dermis	Inflammatory macrophages produces inflammatory cytokines (IL-1 beta, TNF ALPHA; IL-6) Phagocytosis of pathogenic agents and necrotic debris	Repetitive macrophages produces growth factors regulatory cytokines [IL10] Gives de novo fibroblasts and induces their proliferation
3	Mast cell	Papillary and reticular debris	Produces inflammatory mediators involved in allergic responses and asthma and recruitment of immune cells	Induce collagen production (fibrosis) from fibroblasts
4	Eosinophils	Reticular dermis	Defense against parasites. Degranulation; release of. Infiltration the skin tissue during eosinophilic dermatosis	Eosinophils IL 4 production for healing injury
5	Alpha beta T lymphocytes	CD8+: Epidermis. CD4+: Epidermis and papillary dermis	Induces antiviral state in the skin through INF delta mechanism effectors produces cognate cytokines (i.e. INF delta, IL-4, IL-17)	Resolution of wound inflammation through Trg mediated control of inflammatory monocytes
6	Non immune cell i.e., Keratinocytes and fibroblast	Epidermis and reticular dermis	Produces inflammation cytokines during diseases, that is, psoriasis, mitotic stress, or irradiation Produces AMPs in response to bacterial detection	Migrate to close wound re-epithelization and restore barrier function Synthesis collagen fibers and other extracellular matrix components in the wound bed

of mass sales in the papillary dermis upsurges as people become older, and they are most commonly seen around PGP 9.5 + nerve fibers. Using vasoactive intestinal peptide, a peptide has been shown to decrease mast cell degranulation. In muscle granules, mediators such as histamine, sulfated proteoglycans, serotonin, and tryptase can be detected. Because of the massive amount of histamine, they produce and release, mast cells are well-known for their role in allergic reactions. They also make a large amount of prostaglandin. Mast cell can be stimulated to degranulate the allergens through the crosslinking with immunoglobulin E receptors. In allergic reaction, mast cells remain inactive until an Allergen bind to immunoglobulin E.<sup>[22]</sup>

## Eosinophils

These are the cells which get active when any external stimuli or allergen is getting in contact with host lets known more about their function. Eosinophil protein X/eosinophil-derived neurotoxin (EPX/EDN), major basic protein, eosinophil cationic protein, and eosinophil peroxidase are all powerful and hazardous proteins found in eosinophilic granules. Eosinophilic granules from humans and mice contain a range of prepared cytokines and chemokines that are released in response to various stimuli. Piecemeal degranulation is the process through which their granular components are released. This method involves degranulation in modest increments so that the cell's viability is not jeopardized. Cytokines may be chaperoned to secretory vesicles that carry their corresponding receptors, enabling them to be released quickly from eosinophil.<sup>[23]</sup>

## Immunomodulators for Skin

Topical immunomodulators are substances that control the skin's local immunological response. The skin, as the biggest immunological organ, is a target, where antigen presentation and immune response induction are in balance under physiological settings.<sup>[24]</sup>

### IL-10

It is elaborated by several body cell monocytes and macrophages, beta lymphocytes, fibroblast, endothelial, and some epithelial cells. Its major actions are expression of adhesion molecule, immigration of neutrophils and macrophages, roll in fever and shock, and hepatic production of acute phase protein.<sup>[24]</sup>

### IL-6

Its source and target sales of action are comparable. Its main functions include the generation of acute phase proteins in the liver, as well as the differentiation and development of T and B cells.<sup>[25]</sup>

### IL-17

Cluster of differentiation 4 (CD 4) + t cells generate it, and it attacks fibroblasts, endothelial cells, and epithelial cells. Its actions in chronic inflammation include increased cytokine production and neutrophil and monocyte migration.<sup>[26]</sup>

## TNF-alpha

TNF-alpha is a mediator of acute inflammation, while TNF-beta is implicated in cellular cytotoxicity and spleen and lymph node development. Various cells, such as monocytes, macrophages, and mass save basophile, eosinophile, beta cell, and T cell NK cell, produce TNF alpha. TNF-alpha's main functions include: Acute phase protein synthesis in the liver, fever, shock, anorexia, and other systemic symptoms, endothelial agent molecule expression, Boost leukocyte and cytotoxicity, and induction of proinflammatory cytokines.<sup>[27]</sup>

## CD4

CD4 is a glycoprotein that serve as a oreceptor. CD4 is found on the surface of immune cells like dendritic cell, T helper cell, macrophages, and monocytes the main mechanism of CD4 T cell depletion in program cell death apoptosis.

Skin infections and inflammations: Sometimes physical factors such as sun light, chemicals, temperature, or microbes, viruses activate skin immunity and allergic condition or inflammation occurs. Some conditions are discussed here.<sup>[28]</sup>

## Chicken Pox

The varicella zoster virus (VZV) causes this extremely infectious illness. It might create a rash that is itchy and blistery. When a healthy youngster is exposed to VZV, the creation of host IgG, IgM, and IgA begins. VZV is thought to disseminate from mucosal and epidermal sores to the local nerve following initial infection, and then stay latent in the dorsal ganglia.<sup>[29]</sup>

## Cold Sores

It is the herpes simplex virus (HSV) that is to fault. The HSV is classified into two types. Cold sores are produced by the HSV Type 1, whereas genital herpes is caused by the HSV Type 2.<sup>[30]</sup>

HSV is transported to neuronal cell bodies in the dorsal root ganglia near the spinal cord by retrograde microtubules. Within this cluster of nerve cells, the virus is still latent. Periodically, the virus reactivates and travels back into stratified squamous epithelium through anterograde microtubule linked transport, where it is shed into vaginal or oral secretion.

## Miscellaneous

Body tanning due to excess exposure in sun light activates melanin pigment and skin tone darkens. Reduced activity of sweat gland due to infection or any aging effect makes skin dry and itchy. There are many more skin diseases such as dermatitis, eczema, and psoriasis,<sup>[30]</sup> which affects immunisystem of skin.

## Conclusion

Skin has two major layers' dermis and epidermis. Epidermis is the major barrier for body, epidermis and its further layers protect the



body from invasion of foreign bodies such as bacteria, viruses, and microorganisms thus it can be concluded that skin immune system is actively involved in defense mechanism of body.

## Acknowledgment

We are thankful to Principal & Management of Dr. Rajendra Gode institute of Pharmacy, Amravati.

## References

1. Nguyen AV, Soulika AM. The dynamics of the skin's immune system. *Int J Mol Sci* 2019;20:E1811.
2. Kabashima K, Honda T, Ginhoux F, Egawa G. The immunological anatomy of the skin. *Nat Rev Immunol* 2019;19:19-30.
3. Kolarsick PA, Kolarsick MA, Goodwin C. Anatomy and physiology of the skin. *J Dermatol Nurses' Assoc* 2011;3:203-13.
4. Lunjani N, Ahearn-Ford S, Dube FS, Hlela C, O'Mahony L. Mechanisms of microbe-immune system dialogue within the skin. *Genes Immun* 2021;22:276-88.
5. Barcaui Ede O, Carvalho AC, Piñeiro-Maceira J, Barcaui CB, Moraes H. Study of the skin anatomy with high-frequency (22 MHz) ultrasonography and histological correlation. *Radiol Bras* 2015;48:324-9.
6. Gaboriau HP, Murakami CS. Skin anatomy and flap physiology. *Otolaryngol Clin North Am* 2001;34:555-69.
7. Kusuma S, Vuthoori RK, Piliang M, Zins JE. Skin anatomy and physiology. In: *Plastic and Reconstructive Surgery*. London: Springer; 2010. p. 161-71.
8. Pasparakis M, Haase I, Nestle FO. Mechanisms regulating skin immunity and inflammation. *Nat Rev Immunol* 2014;14:289-301.
9. Hershko AY. Insights into the mast cell-microbiome connection in the skin. *J Allergy Clin Immunol* 2017;139:1137-9.
10. Reinholz M, Ruzicka T, Schaubert J. Cathelicidin LL-37: An antimicrobial peptide with a role in inflammatory skin disease. *Ann Dermatol* 2012;24:126-35.
11. Seré K, Baek JH, Ober-Blöbaum J, Müller-Newen G, Tacke F, Yokota Y, *et al.* Two distinct types of Langerhans cells populate the skin during steady state and inflammation. *Immunity* 2012;37:905-16.
12. Romani N, Koide S, Crowley M, Witmer-Pack M, Livingstone AM, Fathman CG, *et al.* Presentation of exogenous protein antigens by dendritic cells to T cell clones. Intact protein is presented best by immature, epidermal Langerhans cells. *J Exp Med* 1989;169:1169-78.
13. Marzulli FN. Barriers to skin penetration. *J Invest Dermatol* 1962;39:387-93.
14. Simmaco M, Mignogna G, Barra D, Bossa F. Antimicrobial peptides from skin secretions of *Rana esculenta*. Molecular cloning of cDNAs encoding esculentin and brevinins and isolation of new active peptides. *J Biol Chem* 1994;269:11956-61.
15. Piktel E, Niemirowicz K, Wnorowska U, Wątek M, Wollny T, Głuszek K, *et al.* The role of cathelicidin LL-37 in cancer development. *Arch Immunol Ther Exp (Warsz)* 2016;64:33-46.
16. Ali SM, Yosipovitch G. Skin pH: From basic science to basic skin care. *Acta Derm Venereol* 2013;93:261-7.
17. Wilgus TA. Immune cells in the healing skin wound: Influential players at each stage of repair. *Pharmacol Res* 2008;58:112-6.
18. Ono S, Kabashima K. Novel insights into the role of immune cells in skin and inducible skin-associated lymphoid tissue (iSALT). *Allergo J Int* 2015;24:170-9.
19. Kawamoto H, Minato N. Myeloid cells. *Int J Biochem Cell Biol* 2004;36:1374-9.
20. Merad M, Manz MG, Karsunky H, Wagers A, Peters W, Charo I, *et al.* Langerhans cells renew in the skin throughout life under steady-state conditions. *Nat Immunol* 2002;3:1135-41.
21. Fujiwara N, Kobayashi K. Macrophages in inflammation. *Curr Drug Targets Inflamm Allergy* 2005;4:281-6.
22. Kritas SK, Saggini A, Varvara G, Murmura G, Caraffa A, Antinolfi P, *et al.* Impact of mast cells on the skin. *Int J Immunopathol Pharmacol* 2013;26:855-9.
23. Moore KW, O'garra A, de Waal Malefyt R, Vieira P, Mosmann TR. Interleukin-10. *Ann Rev Immunol* 1993;11:165-90.
24. De Waal Malefyt R, Hans Y, Roncarolo MG, Spits H, de Vries JE. Interleukin-10. *Curr Opin Immunol* 1992;4:314-20.
25. Van Snick J. Interleukin-6: An overview. *Annu Rev Immunol* 1990;8:253-78.
26. Lindén A, Laan M, Anderson GP. Neutrophils, interleukin-17A and lung disease. *Eur Respir J* 2005;25:159-72.
27. Jang DI, Lee AH, Shin HY, Song HR, Park JH, Kang TB, *et al.* The role of tumor necrosis factor alpha (TNF- $\alpha$ ) in autoimmune disease and current TNF- $\alpha$  inhibitors in therapeutics. *Int J Mol Sci* 2021;22:2719.
28. Zhu J, Paul WE. CD4<sup>+</sup>T cells: Fates, functions, and faults. *Blood* 2008;112:1557-69.
29. Almeida JD, Howatson AF, Williams MG. Morphology of varicella (chicken pox) virus. *Virology* 1962;16:353-5.
30. Chi CC, Wang SH, Delamere FM, Wojnarowska F, Peters MC, Kanjirath PP. Interventions for prevention of herpes simplex labialis (cold sores on the lips). *Cochrane Database Syst Rev* 2015;2015:CD010095.